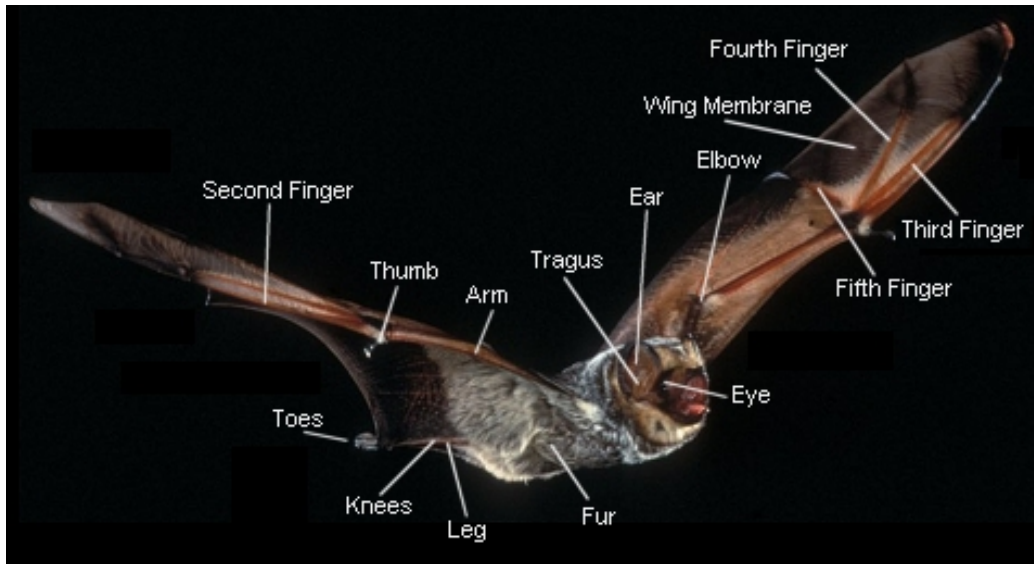


# Bat Anatomy



## Glossary

**Calcar:** A long, bony spur on the bat's ankle that helps support the tail membrane.

**Forearm, fingers, and thumb:** Bats' forelimbs include most of the same components as those of other mammals, but the hands and fingers are elongated to support and manipulate the wings.

**Nose leaf:** A flap of skin above the nostrils of some bats. Among New World species with this feature, it usually is triangular and rises vertically from the tip of the nose.

**Tail membrane:** Also called the "interfemoral membrane," this spans the area between a bat's legs and tail.

**Tragus:** A flap of skin at the base of the external ear. It often rises vertically like a small sword.

**Wing membrane:** A thin double layer of skin that forms the bat's flying surface.